

ATTR polyneuropathy symptom checklist

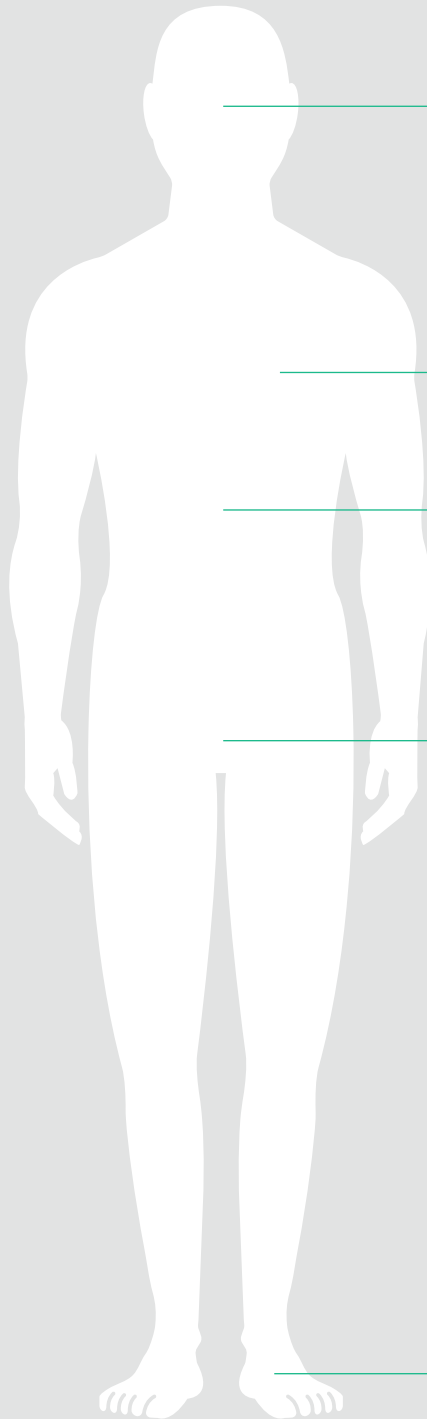
This checklist provides a list of signs and symptoms associated with the rare autosomal dominant disease ATTR polyneuropathy (ATTR-PN) which is often underdiagnosed or misdiagnosed.¹ The results of the checklist will help you decide whether ATTR-PN should be considered in the differential diagnosis of these patients. A positive genetic test of a *TTR* gene mutation along with presentation of these symptoms can confirm a diagnosis of ATTR-PN.¹

AGE

SEX MALE FEMALE

DOES THE PATIENT HAVE A KNOWN FAMILY HISTORY OF ATTR-PN? YES NO

Tick the box if the symptom or sign is reported or observed



Ocular^{1,2}

- Glaucoma
- Vitreous opacities
- Scalloped pupils



Cardiac¹

- Dyspnea on exercise and at rest
- Orthopnea
- Syncope
- Palpitations
- Pulmonary edema



Other^{1,3}

- Unexplained weight loss
- Muscle waste and / or weakness
- Renal disease
- Early satiety
- Dizziness



Autonomic^{1,4,5}

- Sexual dysfunction
- Impaired bladder function
- Orthostatic dizziness / syncope
- Sweating abnormalities / sudomotor dysfunction
- Constipation alternating with diarrhea (*de novo*)



Neuropathic^{1,6,7,8}

- Spontaneous pain
- Evoked pain
- Non-painful sensations
- Light touch, vibratory, proprioceptive sensory loss
- Absent deep tendon reflexes
- Bilateral carpal tunnel syndrome
- Lumbar spinal stenosis
- Pin-prick sensory loss
- Thermal sensory loss
- Allodynia
- Hyperalgesia

Consider these signs and symptoms to recognize ATTR-PN in your patients

This symptom checklist was developed according to recommendations from:

1. Conceicao I, et al. *Amyloid* 2019, DOI: 10.1080/13506129.2018.1556156. [Epub ahead of print];
2. González-López E, et al. *Rev Esp Cardiol* 2017;70:991–1004;
3. Ando Y, et al. *Orphanet J Rare Dis* 2013;8:31.
4. Milani P, et al. *Mediterr J Hematol Infect Dis* 2018;10:e2018022;
5. Mollee P, et al. *Intern Med J* 2014;44:7–17;
6. Siddiqi OK, et al. *Trends Cardiovasc Med* 2018;28:10–21;
7. Mohty D, et al. *Arch Cardiovasc Dis* 2013;106:528–40.
8. Westermark P, et al. Transthyretin-derived amyloidosis: probably a common cause of lumbar spinal stenosis. *Ups J Med Sci.* 2014;119(3):223-22

